



*International Journal
of
Homoeopathic Sciences*

International Journal of Homoeopathic Sciences

Peer Reviewed Journal, Refereed Journal, Indexed Journal

E-ISSN: 2616-4493, P-ISSN: 2616-4485

Publication Certificate

This certificate confirms that "**Dr. Rishi Mohan**" has published manuscript titled "**An individualised approach of homoeopathic medicine in tinea cruris: A case report**".


Details of Published Article as follow:

Volume : **6**
Issue : **2**
Year : **2022**
Page Number : **17-20**

Certificate No.: **6-1-40**

Date: **01-04-2022**

Yours Sincerely,



Akhil Gupta
Manager
International Journal of Homoeopathic
Sciences
www.homoeopathicjournal.com



International Journal of Homoeopathic Sciences

E-ISSN: 2616-4493

P-ISSN: 2616-4485

www.homoeopathicjournal.com

IJHS 2022; 6(2): 17-20

Received: 06-11-2021

Accepted: 16-12-2021

Dr. Ruchira Sharma

Ph.D., Associate Professor,
Department of Homoeopathic
Pharmacy, Swasthya Kalyan
Homoeopathic Medical College
& Research Centre, Sitapura,
Jaipur, Rajasthan, India

Dr. Rishi Mohan

Assistant Professor,
Department of Repertory,
Laxmiben Homoeopathy
Institute & Research Centre,
Bhandu, Mehsana, Gujarat,
India

Dr. Deeksha Sailakwal

Assistant Professor,
Department of Obstetrics and
Gynecology, Laxmiben
Homoeopathy Institute &
Research Centre, Bhandu,
Mehsana, Gujarat, India

Dr. Indra Gaurav Saxena

Assistant Professor,
Department of Repertory,
Faculty of Homoeopathic
Science, Jayoti Vidyapeeth
women's University, Jaipur,
Rajasthan, India

Dr. Daisy Bhardwaj

M.D. (PGR), Department of
Homoeopathic Pharmacy,
Swasthya Kalyan
Homoeopathic Medical College
& Research Centre, Sitapura,
Jaipur, Rajasthan, India

Corresponding Author:

Dr. Ruchira Sharma

Ph.D., Associate Professor,
Department of Homoeopathic
Pharmacy, Swasthya Kalyan
Homoeopathic Medical College
& Research Centre, Sitapura,
Jaipur, Rajasthan, India

An individualised approach of homoeopathic medicine in tinea cruris: A case report

**Dr. Ruchira Sharma, Dr. Rishi Mohan, Dr. Deeksha Sailakwal, Dr.
Indra Gaurav Saxena and Dr. Daisy Bhardwaj**

DOI: <https://doi.org/10.33545/26164485.2022.v6.i2a.531>

Abstract

Tinea is a dermatophytic infection caused by a fungus. Tinea cruris is a type of intertriginous dermatophytoses and include the lesions occurring in groins region. A 21 years old male reported with Tinea cruris from two and a half years. A complete case history was taken and after repertorisation on the basis of totality, Lycopodium in 200 potency was selected and single dose was given. Case was closely followed for two months after that, which shows the effectiveness of homoeopathic medicine in the treatment of Tinea cruris.

Keywords: Tinea cruris, homoeopathy, lycopodium

Introduction

Dermatophytic infections in humans are caused by three genera namely Trichophyton, Microsporon and Epidermophyton. Dermatophytes are fungi which are keratinophilic in nature and live on dead keratin and induce inflammation to the skin, hair & nails. Trichophyton rubrum are the most common dermatophytic infection among the Indians. [1][7] These infection causes inflammation in the skin by permeation of their metabolic products into the layer of skin and by induction of delayed hypersensitivity [2][5]. They generally get worse during the summer and the rainy season and tend to get heal spontaneously during winter.

Clinically the dermatophytoses can be classified into [1].

Tricho-dermatophytoses (dermatophytosis occurring in the hair and the hair follicles):
[Tinea Capitis, Tinea Barbae].

- **Tinea capitis:** These are of three types
- **Non-inflammatory:** Caused by anthrophilic organisms which are less inflammatory occur in epidemics, spread through humans and appears as patches of alopecia in two patterns: Grey patch type and Black/grey dot type.
- **Inflammatory:** Caused by zoophilic/geophilic dermatophytes and appear as patches of alopecia in two patterns: Folliculitis and Kerion.
- **Favus:** Caused by Tinea schoenleinii and appear as foul smelling yellow cup shaped crusts result in cicatricial alopecia [2].

Tinea capitis is commonly seen in children than the adults. And the degree of inflammation depends on the strain of fungus [2].

Tinea barbae: Fungal infection occur in the beard and moustache area of the adults
Tinea barbae is present with perifollicular pustules, papules, erythema, crusting, seropurulent discharge and easy pluckability of hairs. This inflammatory type causes cicatricial alopecia on healing [3].

Intertriginous dermatophytosis: (involving the intertriginous areas that is folds of skin)-
Tinea cruris, Tinea interdigitale, Tinea axillariss

- **Tinea cruris:** Fungal infection of the groin region are very common condition, occurs in summer and rainy season due to use of synthetic clothes and effects men more often than the women and is less common in children.

Arcuate or annular lesions with scaling, papulovesicular and pustulation. Chronic lesions may show hyperpigmentation, nodulation and lichenification [2].

- **Tinea interdigitale and Tinea axillaris:** Fungal infection of the finger, toes and axillae occur due to heat accumulation and humidity in the fold of skin which promote fungal infection. Lesion resembles the glabrous dermatophytosis and show a well-defined papule-vesicular border and sometimes maceration also [1].

Glabrous dermatophytosis: Involves non-hairy skin - Tinea corporis

- a) **Tinea corporis:** Annular/arcuate lesions with clearing in center and active periphery. Affects glabrous skin except palms, soles, groins [6]. It has two variants:
 - **Tinea incognito:** Dermatophytic infection of skin, modified by steroid therapy.
 - **Tinea faciae:** Annular scaly patches seen on cheeks of children.

Palmo-Planter dermatophytes: Involve skin areas having thickened stratum corneum - Tinea pedis, Tinea manuum.

- a) **Tinea Pedis:** (Tinea of foot) occurs due to hyperhidrosis of soles and occlusive foot wear. It's three clinical patterns are recognized: Interdigital variant, Vesicular variant, Hyperkeratotic variant [2].
- b) **Tinea Mannum:** (Tinea of hands) unilateral, well-defined plaques of the palm with well accumulation of fine scales in the creases [2].

Ungual Dermatophytoses: (involving the nails)- Tinea unguium

- a) **Tinea Unguium:** It is dermatophytic infection of nails caused by *Tricophyllum rubrum*, *Tricophyllum mentagrophytes*, *Epidermophyton floccosum*. Tinea of toe nail is more frequent than finger nails as it involves distal parts for onset. It usually affects only few nails with involvement being asymmetrical and the nail shows yellow brownish discoloration and thickened plate which crumbles easily and the collection of debris under the nail. It separates the nail plate from the nail bed. Several patterns are being recognized: Distal/lateral subungual variety, superficial white variety, proximal subungual variety. [2][5]

Pathology

Human fungal infections are opportunistic that is, they occur in conditions with impaired host immune mechanism. Fungal hyphae and spores of dermatophytes are present in the stratum corneum of skin, nails or hair. Hyphae may be septate or nonseptate. Spores are round to oval bodies which grow by budding. Special stains are used to demonstrate the fungi [4].

Case Study

A 21 years old unmarried Hindu male having whitish complexion and horizontal wrinkles on forehead belonging from middle socio- economic status reported in OPD on 31st July 2019, with complaint of Tinea on both the buttocks. His height was 5'4" and built was normal. He had Tinea on the buttocks since two and a half years with itching. Itching gets worse on wearing tight clothes, on changing clothes and on eating fish and better by scratching, applying cold

things and by bathing. Firstly lesion appeared in the groin region with itching. Patient said he was taking alternative treatment along with external applications from long time due to which, he observed that the Tinea spread from groin region to buttocks region.

Clinical Findings: Tinea on both the buttocks since two and a half years. Itching was present.

Past History: History of typhoid in 2015, dengue in 2016

Family history: Mother – Diabetes and stammering

Physical Generals: Patient desired salty and sour things. He had aversion from fish, curd; brinjal as all these things aggravates his itching. Perspiration was profuse and offensive, especially on neck & axilla. He was thirsty & thermal reaction of the patient is hot. His sleep was disturbed due to itching.

Mental Generals: He has the problem of stammering since he was of 10 years of age; he hesitates in communicating with others. He doesn't want to do his B.Ed. because of his stammering. He thought that people will laugh on him. When he get anger he sits alone in a room and weeps as he doesn't want others to be get hurt because of him. He thinks that he is not reaching up to the expectations of his family. His father is a vegetable vendor and he doesn't want to do this work as he says he is an educated person and this work is not suited for him.

Analysis of case

Mental Generals

- Lack of confidence
- Reserved
- Weeping alone
- Stage fear

Physical Generals

- Appearance- wrinkles on forehead
- Desire- salty and sour things
- Aversion- fish⁺⁺⁺, brinjal, curd
- Perspiration- increase in neck and axilla, offensive
- Thermal- Hot
- Sleep- disturbed due to itching

Particulars

- Ringworm on buttocks
- First appear on groin region
- Itching is present
- Modalities- < on changing clothes < fish < tight clothes > scratching > bathing

Evaluation

- Confidence want of self
- Reserved
- Weeping alone
- Wrinkles on forehead
- Perspiration offensive
- Ringworm on buttocks
- Itching present
- Modalities << fish

Table 1: Rubrics

S. No.	Chapter	Rubric
1	Mentals	Confidence want of self
2	Mentals	Reserved
3	Mentals	Weeping, alone, when general
4	Face	Wrinkled, general forehead
5	Lower Extremities	Lower Extremities buttocks
6	Extremities	Itching buttocks, nates
7	Perspiration	Odor offensive
8	Skin	Trichophytosis
9	Generals	Food and drinks, fish agg.

Repertory sheet [8].

	Lyc	Sulph	Am-c	Ars	Calc	Caust	Graph	Rhus-t
Weighted	15	13	7	8	7	9	12	8
Rubrics covered	9	7	6	6	6	6	6	6
Rubric grades	15	13	7	8	7	9	12	8
C Mentals	2	1	1	1	1	1	1	1
C Mentals	1	1	1	1	2	1	1	
C Mentals	1			1				
C Face	3	2	1			2	2	1
C Extremities	1	3	2		1	2		
BH Lower Extrem	2	2	1		1	2	3	2
C Skin	1	1		2	1		2	1
C Perspiration	3	3	1	2	1	1	3	2
C Generals	1			1				1

Fig 1: Showing repertorization of case from Complete Repertory using Cara Professional (Version 1.4)

Analysis of Repertorial Result

Table 2: Repertorial Result

S. No.	Medicine	Mark Obtain
1.	Lycopodium	15/9
2.	Sulphur	13/7
3.	Ammonium carbonicum	7/6

Selection of Medicine: Lycopodium is the remedy selected in this case as it covers all the rubrics and obtains highest marks in repertorization. Lycopodium covers the other general symptoms also like offensiveness of secretion, hot and thirsty and stammering. While Sulphur do not cover the aggravation from fish eating and in Sulphur complaints are aggravated from bathing. Ammonium carbonicum is very chilly in thermal. Lycopodium [9, 10] in 200C potency is selected in this case according to the susceptibility.

Table 3: Prescription

Date	Symptoms	Prescription
31/07/2019	Tinea on buttocks Intense itching Stammering Offensiveness of secretion Advice-To apply coconut oil on eruptions-Keep the area dry-Wear only cotton clothes	Lyco. 200 1Dose Stat. Phytum 30 TDS 6 hourly * 7 Days

Table 4: Follow Up

Date	Symptoms	Prescription
07/08/2019	Tinea still same Slight relief in itching No relief in stammering Relief in offensiveness of secretion	Phytum 30 TDS 6 hourly * 10 Days
19/08/2019	Tinea gets lighter in colour Size gradually decreases No relief in stammering	Phytum 30 TDS 6 hourly * 10 Days
29/08/2019	Tinea gradually decreasing Skin appears healthy No relief in stammering	Phytum 30 TDS 6 hourly * 15 Days
14/09/2019	Improvement. Skin appears healthy Slight improvement in stammering	Phytum 30 TDS 6 hourly * 15 Days
30/09/2019	Improvement. Slight improvement in stammering	Phytum 30 TDS 6 hourly * 15 Days

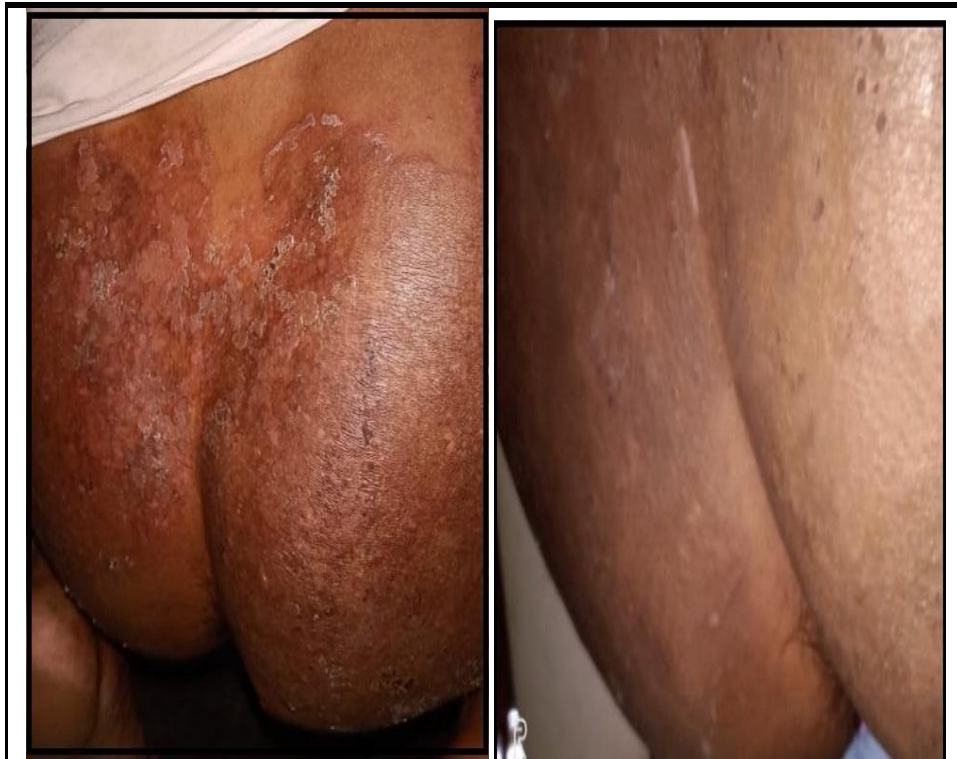

Fig 2: Before & After Pictures

Conclusion

Homoeopathy is specialised system of medicine which treats the patient as a whole and not just the disease. In this case patient improved symptomatically gradually after prescription of *Lycopodium* in 200 in centesimal scale potency and single dose. This case shows the effective role of Homoeopathy in the treatment of *Tinea cruris*. This case reflects the role of constitutional remedy in holistic improvement of patient's mental health by improving his confidence level and slight improvement in stammering than before. Now he is preparing for government exams. The patient showed improvement in beginning which proved correct selection of medicine. This case shows positive role of individualized homoeopathic medicine in effective treatment.

Declaration of patient consent

The authors certify that they have obtained appropriate patient consent forms; the patient has given consent for his images and other clinical information to be reported in the journal.

Financial support and sponsorship: Nil

Conflict of interest: There is no conflict of interest.

Reference

1. Pasricha JS, Gupta Ramji Illustrated Textbook of Dermatology common. 4th Edition. Jaypee Brothers Medical Publishers (p) Ltd, 2013.
2. Khanna Neena. Illustrated Synopsis of Dermatology and Sexually Transmitted Diseases. 5th Edition. Elsevier. 2016.
3. Sainani GS, Abraham Dastur FD, Abraham P, Dastur FD, Joshi VR, *et al.* A.P.I. Text Book of Medicine. 6th Edition. Association of Physicians of India Mumbai, 1999.
4. Mohan Harsh. Textbook of Pathology. 5th Edition. Jaypee Brothers Medical Publishers (p) Ltd, 2005.
5. Hunter JAA, Savin JA, Dahl MV. Clinical Dermatology, 3rd edition, Blackwell Publishing, Pg. No. 55.
6. Puttini P, Doria A, Girolomoni G, Kulm A. The Skin in Systemic Autoimmune Disease, Handbook of Systemic Autoimmune Disease, Vol-5, Elsevier, 2006, 94-98.
7. Davidson's. Principles and Practice of Medicine. (23rd ed.): Elsevier Ltd.
8. Complete Repertory, Cara Pro. 1.4.
9. Allen HC. Allen's Key Notes, Rearranged and Classified with Leading Remedies of the Materia Medica and Bowel Nosodes, Eighth Edition, B Jain Publisher (P) Ltd, New Delhi, 2016.
10. Kent JT. Lectures On Homoeopathic Materia Medica, Low Price Edition 15th Impression, B Jain Publisher (P) Ltd, New Delhi, 2015.